

A Case report and review of the literature of Unicysticameloblastoma with Impacted Third Molar in A 15-Year old Female

Dr. Maged Ali Ali¹, B.D.S. Dr. Omar.A. Rageh², B.D.S Dr. Mohammed
Sheikh³ B.D.S

Department Of Oral And Maxillofacial Pathology, Faculty Of Oral & Dental Medicine - Cairo University

Abstract: According to the 2005 histological classification of odontogenic neoplasms by the World Health Organization, ameloblastoma is a benign, locally invasive epithelial odontogenic tumor of putative enamel organ which usually affects the mandible. Unicysticameloblastoma (UA) refers to those cystic lesions that show clinical, radiographic, or gross features of a mandibular cyst, but on histologic examination show a typical ameloblastomatous epithelium lining part of the cyst cavity, with or without luminal and/or mural tumor growth. It accounts for 5-15% of all intraosseous ameloblastomas. We report a case of unicysticameloblastoma in a 15-year-old female, and review the literature..

Keywords: Ameloblastoma; Radiolucency; Fine needle aspiration ; Unicysticameloblastoma

I. Introduction

Various benign lesions cause mandibular swellings, and these can be divided into odontogenic and nonodontogenic origin. The most common tumor of odontogenic origin is ameloblastoma which progresses from epithelial cellular elements and dental tissues in their different phases of development. (Nagalaxmi et al. 2013)

Ameloblastoma is a local invasive and aggressive tumor, the source of epithelium may be enamel organ, remnants of dental lamina or Hertwig's epithelial root sheath, lining of odontogenic cysts or basal epithelial cells of oral mucosa and it accounts for only 1 % of all oral neoplasms. Based on the World Health Organization (WHO) classification of head and neck tumours, there are four types of ameloblastomas: multicystic, desmo- plastic, peripheral and unicysticameloblastomas (Agani et al. 2016).

Unicysticameloblastoma (UA) as a separate entity was first described by Robinson and Martinez in 1977. It arises as a de novo neoplasm and not following secondary cystic changes in the solid counterpart. (Chaudhry et al. 2015). Occasionally these can present as a multilocular radiolucency which creates the use of the term "cysticameloblastoma" more suitable. However, some authors still consider that the notion that cystic ameloblastomas can have a "true" clinically multicystic pattern is questionable and contend with the use of the term "unicysticameloblastoma". It occurs in a younger population mainly in 2nd and 3rd decade as compared to conventional ameloblastoma which occurs over a wide age range. Most common site of occurrence is mandible associated with an impacted tooth, usually the 3rd molar. Radiographically, the UA is associated with a unilocular radiolucency having scalloped or lobulated border. (Arora 2015)

II. Case Report

A 15-year-old female reported to our outpatient oral and maxillofacial department reported with the chief complaint of gradually increasing swelling on the left-side of face since last 6-7 months.

Patient was observed a swelling and displacement of the left second lower molar and reports of having pain in the same region. Pain was of dull aching type, which was intermittent, and it exacerbates on putting mastication and releases on rest. Pain was not related with fever and no medication was taken.

Extra-oral examination showed a diffuse, firm, asymptomatic swelling over the left ramus area, which was nearly 5 × 4 cm in size. Superiorly, it was extending up to the tragus, inferiorly up to the lower border of mandible, anteriorly up to a point 4 cm lateral to the angle of the mouth and posteriorly up to the posterior border of the ramus. There was difficulty in mouth opening. Overlying skin was normal; no visible pulsations and no discharge were seen. On palpation, the swelling was firm in consistency. Left submandibular lymph nodes were palpable, firm, tender and movable. (Figure 1)

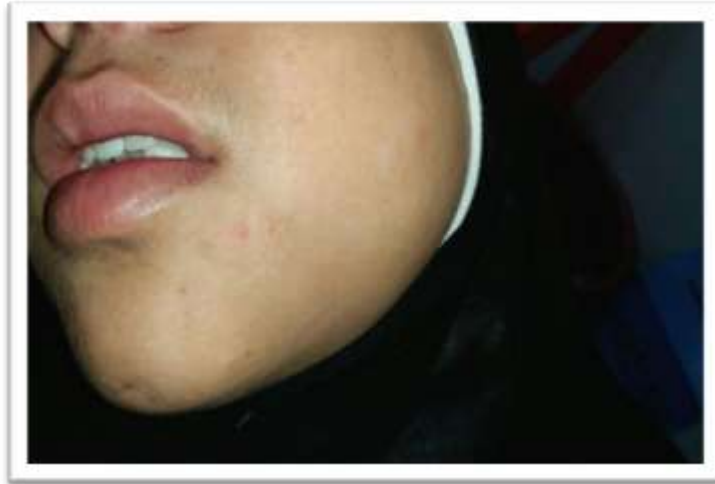

Fig-1.Extra-oral view

Intraorally, a well-defined, firm swelling was seen extending posteriorly upwards from lower left second molar region. The left third molar was clinically missing. There was expansion of the buccal cortical plate and loss of the buccal vestibular depth. There was mobility in the second molar. (Figure 2)

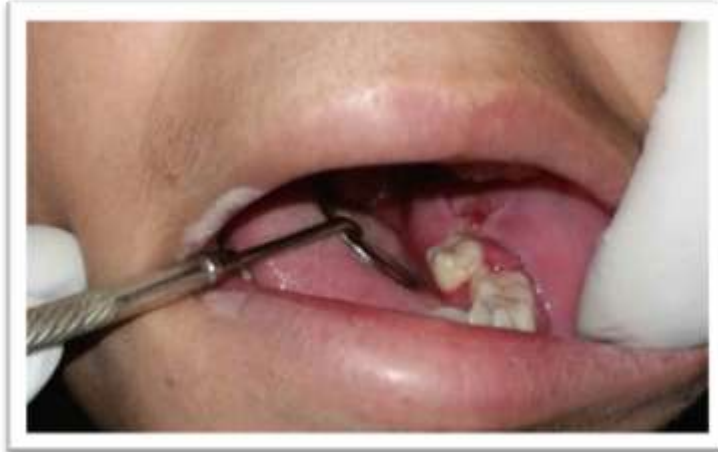

Fig 2.Intraoral examination

Investigations

1-On fine needle aspiration FNA reddish fluid was aspirated (Figure 3) and a routine complete blood picture were done, which were normal.

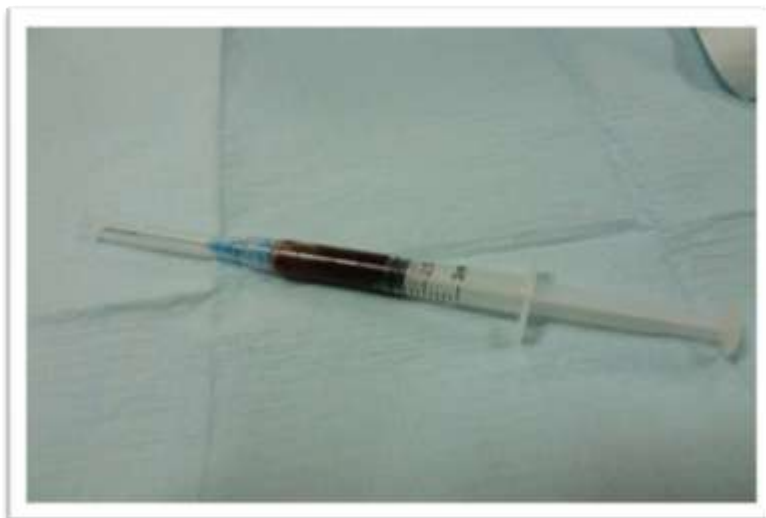

Fig 3. FNA

2-Radiographic (multi-slice CT examination of the facial bones revealed :

A large thin wall cystic lesion is seen arising from the left mandibular body measuring about 6x5 cm containing a tooth and clear fluid density inside, the lesion causes contour bulge of the left side of face and displacing the overlying musculature with destruction to the ascending ramus, coronoid process and angle of mandible(Figure 4.a-b).

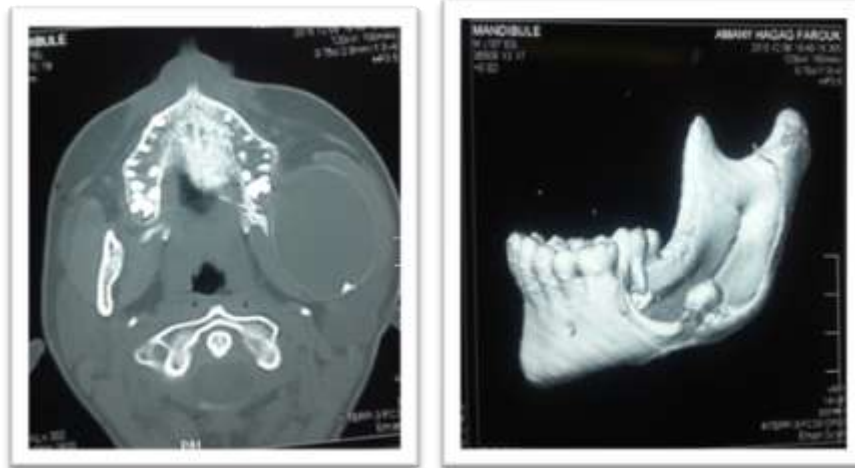

Fig 4 a.b. Radiographic (multi-slice CT examination) showing huge radiolucency extending from the mesial root of the second molar with impacted third molar to coronoid notch involving the angle and ramus of the mandible

Patient forwarded for surgery and the excision of the swelling we received fragments of hard tissue masses the largest one was (3x1) cm, adherent to the impacted tooth third molar, firm in consistency and brownish in color. (Figure 5) and sent the sample for histopathological examination (HPE).



Fig 5. Grossly specimen

Microscopy: Histopathological examination of H&E stained sections revealed the cystic lining lined by ameloblastomatous epithelium overlying with stellate reticulum like cells (Figure 6a). Proliferation of this ameloblastomatous epithelium is seen both in the lumen and as well as in the connective tissue capsule of the cyst (Figure 6b)

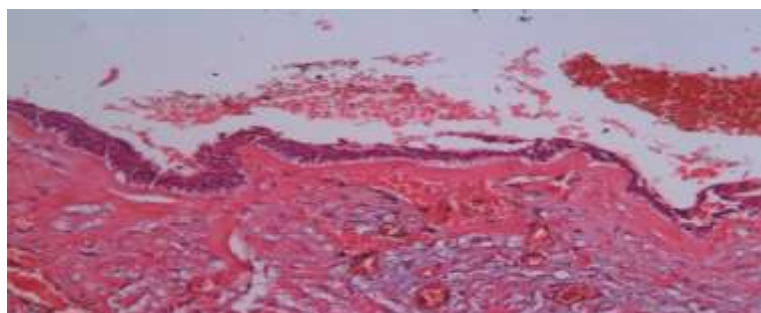


Fig 6.a Showing luminal UA with tall columnar ameloblast like basal cells and stellate reticulum like superficial cells

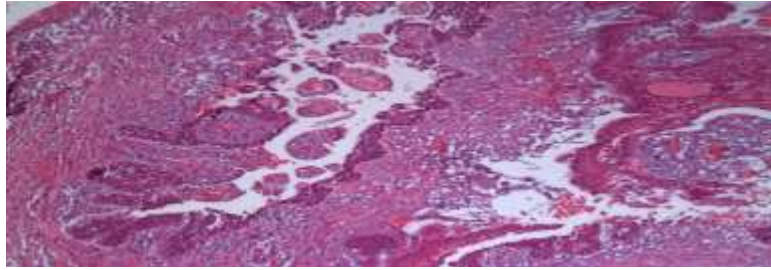


Fig 6.b Section showing intraluminal proliferation

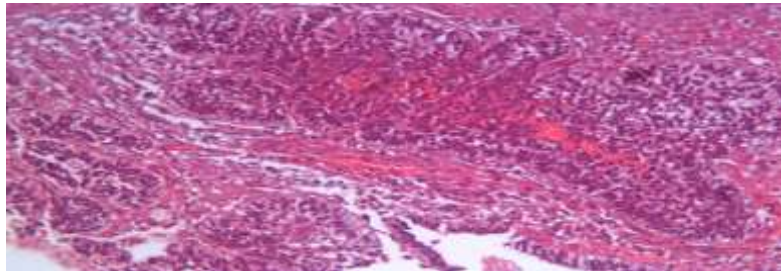


Fig 6.cSection showing intramural proliferation

VI. Discussion

Ameloblastoma is a benign, locally destructive odontogenic neoplasm with variable clinical appearance and accounts for 1% of all cysts/tumors of jaws and 17% of all odontogenic neoplasms. It is typically slow growing, locally aggressive and rarely metastasizes but has a great rate of recurrence (60–90%) if not removed sufficiently. According to WHO system of 2005, the term ameloblastoma includes several clinicoradiological and histological types. It is classified into four types; conventional solid (multicystic), unicystic, desmoplastic and peripheral varieties. Unilocular ameloblastoma (UA) is a rare type of ameloblastoma, accounting for about 6% of ameloblastomas (Laxmidevi et al. 2015).

It frequently occurs in a younger age group, with about 50% of the reported cases taking place in the second decade of life. More than 90% are placed in the mandible. Between 50 and 80% of cases are connected with tooth impaction, the mandibular third molar being most often involved. (UA) may originate de novo as a neoplasm or from the epithelium lining of an odontogenic cyst. (UA) is measured to be less violent compared with conventional ameloblastoma both in its growth pattern and recurrence rate (Ramesh et al. 2010)

In furthermost of the cases, radiographic diagnosis of dentigerous cyst was made bearing in mind the age and the lesion was surgically removed and whole tissue was subjected to histopathological diagnosis. It is, therefore, suggested that, because the diagnosis of UA is made in a postoperative phase by a careful histopathological examination of more serial sections and because incisional biopsy may not be able to reveal the true nature of the lesion, so to have appropriate diagnosis whole tissue must be included for histopathological examination. (Arora 2015)

V. Conclusion

UA is a type of ameloblastoma, occurs more frequently in second decade of life, offerings clinically as a painless swelling in mandible and unilocular radiolucency in most of the cases. Most of these lesions when occur in the mandibular third molar region with impaction, they are usually removed on radiographic diagnosis of dentigerous cyst and then the specimen is subjected to histopathological which show a typical ameloblastomatous epithelium lining part of the cyst cavity.

Reference

- [1]. Agani, Z. et al., 2016. Maxillary unicystic ameloblastoma: a case report. BMC Research Notes, 9(1), p.469. Available at: <http://bmcresnotes.biomedcentral.com/articles/10.1186/s13104-016-2260-7>.
- [2]. Arora, S., 2015. Unicystic Ameloblastoma: A Perception for the cautious interpretation of radiographic and histological findings. Journal of the College of Physicians and Surgeons Pakistan, 25(10), pp.761–764.
- [3]. Chaudhry, A. et al., Extensive Type III Unicystic Ameloblastoma – A Case Report with Conservative Management. , (617), pp.202–205.
- [4]. Laxmidevi, B., Mohammed, M. & Ashok Kumar, K., 2015. Unicystic ameloblastoma with impacted third molar mimicking dentigerous cyst. Journal of Interdisciplinary Dentistry, 5(1), pp.37–40. Available at: <http://www.jidonline.com/text.asp?2015/5/1/37/162743>.
- [5]. Nagalaxmi, V. et al., 2013. Unicystic mural ameloblastoma: an unusual case report. Case reports in dentistry, 2013, p.957418. Available at: <http://www.pubmedcentral.nih.gov/articlerender.fcgi?artid=3655499&tool=pmcentrez&rendertype=abstract>.
- [6]. Ramesh, R.S. et al., 2010. Unicystic ameloblastoma of the mandible -- an unusual case report and review of literature. Journal of Head Neck Oncology, 2(Figure 6), pp.1–5.